

A Shoulder-Facial Synkinesis in Normal Human Subjects

Joel Fuhrman, M.D.*, Michael E. Selzer, M.D., and Frederick S. Kaplan, M.D.

Abstract

We noted the involuntary elevation of the nasolabial fold in association with voluntary posterior circumduction of the contralateral upper limb in more than 90% of normal human subjects. Circumduction begins with the arms dependent and adducted, and progresses posteriorly in a manner similar to the movement performed by a freestyle swimmer. The nasolabial fold elevation did not occur with passive circumduction. The response was reproducible, asymmetric, did not fade with repetition and did not correlate with handedness. This is the first description of a limb-face synkinesis in normal human subjects.

Introduction

Synkinesis refers to the simultaneous contraction of muscles which do not normally act together [6]. Synkinetic phenomena often result from birth trauma. Adult cases rarely occur and are usually the sequelae of Bell's Palsy or traumatic nerve lesions [2,9]. The pathological synkineses are important because they exemplify patterns of central or peripheral neural regeneration [8]. While the synchronous closure of one eye with reflexive blink of the contralateral eye or the elevation of the eyes during lid closure might be termed synkineses, normal synkineses have not been previously described between appendages and the face. We observed an involuntary contralateral elevation of the nasolabial fold in normal human subjects when the arms were circumducted posteriorly. We undertook this study in order to better understand the prevalence of this synkinesis in normal adults.

Subjects and Methods

One hundred ten consecutive volunteers were tested. Students and medical personnel at the University of Pennsylvania were asked to volunteer for "a research study of shoulder mobility." Subjects with a previous history of shoulder or neurologic disorder or any facial or reconstructive surgery were excluded. Only one person was excluded because of these criteria. Handedness was also recorded.

There were fifty-seven men and fifty-three women with ages ranging from sixteen to sixty-six, and a median age

of thirty-one. Each volunteer was asked to move the arms in the described fashion without knowledge of the true purpose of the test and without knowledge that they were being observed for a possible facial response. They were first asked to circumduct the arms simultaneously. The movement began with the arms at the sides and the elbows in extension. The hands were thrust posteriorly in a manner similar to that during swimming the butterfly stroke. The arms remained extended and the forearms supinated until the limit of shoulder posterior extension was reached (approximately 90° from the vertical body axis). At that point a slight abduction and pronation was allowed in order to complete the circle. The movement was meant to be rapid and the effect was described by one observer as "windmilling" in the anterior-posterior direction. Subjects were asked to perform the movement continuously at one to two cycles per second and to maintain the movement for ten seconds. The phenomenon was recorded as being present if it occurred even once during the 10 second trial. However, if it was present at all in a given subject, it occurred in almost every cycle. Each volunteer was subsequently asked to repeat the movement with only one arm and then the other. The examiner demonstrated the motion, if needed. The examiner then attempted to elicit the facial response by moving the subject's arm passively in the same pattern.

One of us (JF) observed all 110 subjects and recorded the results for the following motions.

1. Active circumduction, bilateral.
2. Active circumduction, unilateral.
3. Passive circumduction, bilateral.
4. Passive circumduction, unilateral.

Each facial response was graded on a 0-4 scale as follows:

- 0 = no observable response.
- 1 = slight elevation of upper lip.
- 2 = pronounced elevation of upper lip.
- 3 = pronounced elevation of the upper lip with slight deepening of the nasolabial fold.
- 4 = pronounced elevation of the upper lip with pronounced deepening of the nasolabial fold.

The scores for each subject reflected the most pronounced facial movement observed during the ten second trial. During bilateral synchronous arm circumduction, the score reflected the most pronounced facial movement on either side. The Chi Square test was used to make comparisons between right and left-handers and between men and women.

*Completed this work while a student at The University of Pennsylvania School of Medicine (M.D., 1988)

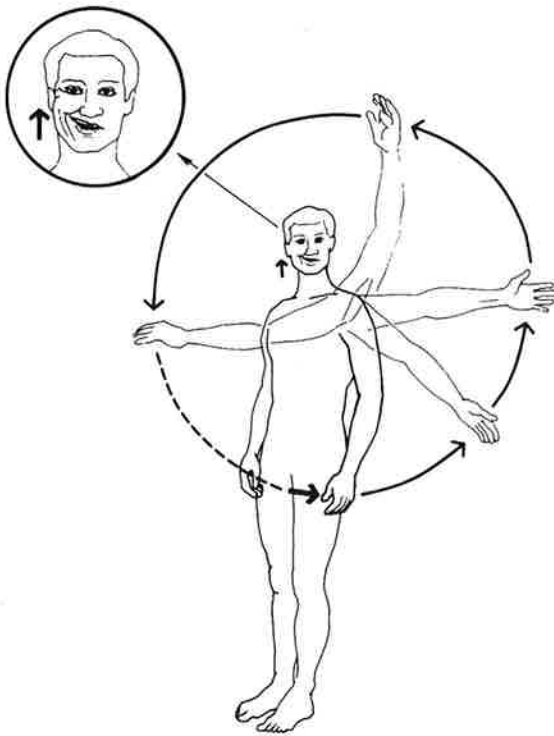


Fig. 1. Diagrammatic depiction of a grade-4 shoulder-facial synkinesis on right, elicited by contralateral active circumduction of the left arm.

Results

One hundred two of the 110 volunteers (93%) had at least slight elevation of one or both upper lips with active simultaneous circumduction of both arms (Table 1). No subject had an observable response to passive motion.

Table 1. Bilateral Simultaneous Arm Circumduction

Score	Men	Women	Total
0	1	7	8
1	22	23	45
2	19	12	31
3	7	8	15
4	8	3	11
totals	57	53	110

Fifty-nine of 110 subjects had a positive response to left arm circumduction and sixty-five had a positive response to right arm circumduction (Table 2).

Table 2. Unilateral Active Arm Circumduction

Score	Men		Women	
	Left Arm	Right Arm	Left Arm	Right Arm
0	26	21	25	24
1	18	20	16	18
2	4	9	8	5
3	6	5	3	4
4	3	2	1	2
totals	57	57	53	53

Sixty-eight subjects had a positive response to the unilateral test on at least one side. In each case, the facial response was on the side contralateral to the active arm. Although an asymmetric response was often seen, it did not correlate with handedness. There were twenty-three right-handed subjects who responded to the unilateral test with unequal scores when comparing the two sides. Twelve had a larger contralateral facial response with movement of the right arm and eleven had a larger response with the left arm. Of the ten left-handed subjects, three had unequal scores when comparing sides. Two subjects had a larger response with movement of the right arm and one with movement of the left arm. No differences were noted between left- and right-handed individuals by Chi Square Test for probability level $p = 0.05$.

There was a statistically significant difference between men and women. The mean score for women was 1.57 versus 1.98 for men. Comparing the number of zero responses in women versus men for the bilateral circumduction (men: 1 in 57; women: 7 in 53), the null hypothesis that there is no difference between men and women was rejected by the Chi Square Test for $p = 0.05$.

Discussion

Muscles of the face have not been reported to contract simultaneously with shoulder strain. In our subjects, the facial contraction occurred involuntarily and in the identical nerve branch distribution in more than 90% of normal subjects when both arms were circumducted simultaneously. When only one arm was rotated, the synkinesis was weaker and failed to be elicited at all from 44% of the subjects. Nevertheless, when it did occur, it was always contralateral to the rotated arm.

The involuntary movement elicited by the arm motion is limited to the muscle group supplied by the upper deep branch of the buccal branch of the facial nerve [10]. This small nerve branch passes under the zygomaticus major and the levator labii superioris, supplying them and then innervates the levator anguli oris, the zygomaticus minor, and the levator labii superioris alaeque nasi [10]. This muscle group elevates the upper lip. These muscles have also been described occasionally as being supplied by a lower zygomatic branch, which most frequently aids in the supply of the zygomaticus muscles [3,10]. The same muscles, particularly the levator labii superioris, the zygomaticus minor and levator anguli oris, produce and deepen the nasolabial furrow, and may be involved in normal smiling.

Of crucial significance to the physiology of the synkinesis is the fact that an active intention is necessary on the part of the subject. The response was reproducible, asymmetric, and did not fade with repetition. If it could be elicited with the mechanism described, it was observable on oneself in a mirror. It could often be observed in persons putting on a coat or sweater.

It should be noted that subjects were not aware that a facial movement was being investigated. The authors

and their associates have reproduced the synkinesis on themselves and are not aware of it when it occurs unless viewing it in a mirror. It has not been possible to suppress the synkinetic movement without altering the arm movement.

This report of a shoulder-facial synkinesis in normal subjects illustrates an interesting previously unreported feature of normal physiology. Prior reports of synkinesis have dealt mainly with the pathologic response of a nerve to injury, illustrative of aberrant axonal regeneration [1,4,5,7]. The synkinesis in the present report illustrates a physiologic relationship between the motor control of the shoulder girdle and that of the upper deep branch of the buccal branch of the facial nerve. The clinical significance of the shoulder-facial synkinesis in health and disease remains to be determined.

Acknowledgement: This work was supported in part by a grant in Research in Aging from The Hartford Foundation.

References

- [1] Auger, R.G.: Hemifacial Spasm: Clinical and Electrophysiologic Observations. *Neurol* 29:1261-1272, 1979.
- [2] Cherington, M., Stears, J., Ryan, D.W., and Platt, F.: Diaphragm-Deltoid Synkinesis with Myelographic Demonstration to the Cause. *Neuroradiol* 2:227-229, 1971.
- [3] DeJong, R.: *The Neurological Examination*. Fourth Edition. New York. Harper and Row, 1979, p 180.
- [4] Kumagami, H.: Neuropathological Findings of Hemifacial Spasm and Trigeminal Neuralgia. *Arch Otolaryngol* 99: 160-164, 1974.
- [5] Neilson, V.K.: Pathophysiology of Hemifacial Spasm: I. Ephaptic Transmission and Ectopic Excitation. *Neurol* 34: 418-426, 1984.
- [6] Robinson, P.K.: Associated Movements between Limb and Respiratory Muscles as a Sequel to Brachial Plexus Birth Injury. *Bull Johns Hopkins Hosp* 89:21-26, 1951.
- [7] Sadjadpour, K.: Postfacial Palsy Phenomena: Faulty Nerve Regeneration or Ephaptic Transmission? *Brain Res* 95: 403-406, 1975.
- [8] Schwarz, G.A.: Posttraumatic Respiratory-Biceps Brachii Synkinesis. *Arch Neurol* 13:427-431, 1965.
- [9] Wartenberg, R.: Associated Movements in the Oculomotor and Facial Muscles. *Arch Neurol Psych* 55(5):439-488, 1946.
- [10] Williams, P.L.; and Warwick, R.: *Gray's Anatomy*. 36th Edition. Philadelphia. W.B. Saunders Company, 1980, p 1070.